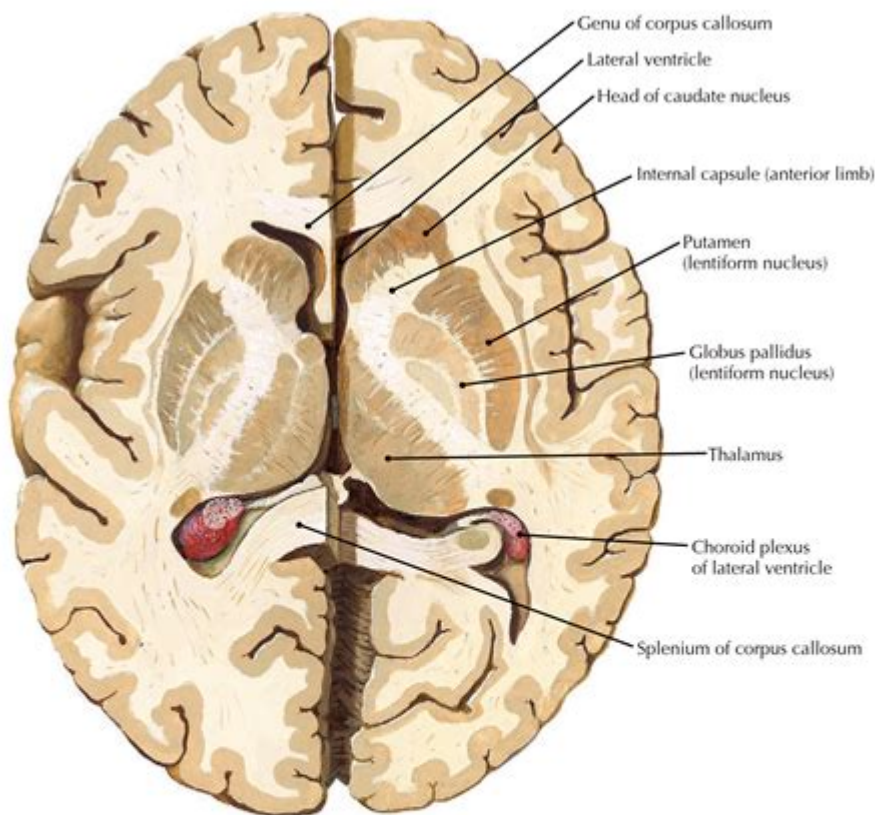


# Axial Brain Anatomy



**AXIAL SECTION THROUGH THE BASAL GANGLIA; THE LEFT AND RIGHT SECTIONS ARE AT SLIGHTLY DIFFERENT TRANSVERSE PLANES**

## **Axial Brain Anatomy: A Comprehensive Guide**

### Introduction:

Delving into the intricate world of the human brain can feel like exploring a vast, uncharted territory. Understanding its complex structure is crucial for comprehending neurological function and dysfunction. This comprehensive guide focuses on axial brain anatomy, providing a detailed look at the brain's structure as visualized in axial (horizontal) slices. We'll journey through key anatomical landmarks, exploring their locations and functions, making this complex subject accessible and engaging for students, healthcare professionals, and anyone fascinated by the human brain. This post will equip you with a solid understanding of axial brain anatomy, empowering you to navigate the brain's complex landscape with confidence.

# Understanding Axial Brain Slices

Before we dive into specific structures, it's vital to grasp the concept of axial imaging. Axial views, also known as transverse or horizontal planes, provide a cross-sectional view of the brain as if it were sliced horizontally. This perspective offers a unique understanding of the brain's internal organization, revealing the relationships between different structures not readily apparent in other imaging planes (sagittal and coronal). Understanding axial views is fundamental to interpreting neuroimaging studies like CT scans and MRI scans.

## Key Anatomical Landmarks in Axial Brain Anatomy

### Cerebrum: The Seat of Higher Cognition

The cerebrum, the largest part of the brain, dominates axial views. Its characteristic convoluted surface, marked by gyri (ridges) and sulci (grooves), is clearly visible. Axial slices reveal the symmetrical arrangement of the cerebral hemispheres, connected by the corpus callosum, a vital structure for interhemispheric communication.

#### Key Cerebral Structures in Axial Views:

**Frontal Lobes:** Responsible for executive functions, planning, and voluntary movement, the frontal lobes appear prominently in anterior axial slices.

**Parietal Lobes:** Crucial for sensory processing, spatial awareness, and navigation, these lobes are seen in mid-axial slices.

**Temporal Lobes:** Essential for auditory processing, memory, and language comprehension, the temporal lobes are visible in inferior axial slices.

**Occipital Lobes:** Primarily responsible for visual processing, the occipital lobes are located at the posterior aspect of the brain.

### Cerebellum: The Master of Coordination

The cerebellum, located inferior to the cerebrum, is easily identifiable in lower axial slices. Its characteristic tree-like branching pattern (arbor vitae) is a distinguishing feature. The cerebellum plays a crucial role in motor control, coordination, balance, and posture.

# Brainstem: The Vital Connection

The brainstem, connecting the cerebrum and cerebellum to the spinal cord, is a crucial structure visible in multiple axial slices. It consists of the midbrain, pons, and medulla oblongata, each playing vital roles in regulating essential functions like breathing, heart rate, and consciousness.

#### Key Brainstem Components in Axial Views:

Midbrain: Plays a critical role in visual and auditory reflexes.

Pons: Involved in sleep-wake cycles, breathing, and relaying sensory information.

Medulla Oblongata: Controls vital autonomic functions like heart rate and respiration.

# Ventricles: The Brain's Fluid-Filled Cavities

The brain's ventricular system, a network of fluid-filled cavities, is readily apparent in axial views. These ventricles produce and circulate cerebrospinal fluid (CSF), which cushions and protects the brain. The lateral ventricles, third ventricle, and fourth ventricle are all visible in different axial planes.

# Clinical Significance of Axial Brain Anatomy

Understanding axial brain anatomy is paramount in various clinical settings. Neurologists, neurosurgeons, and radiologists utilize axial imaging to diagnose and manage a wide range of neurological conditions, including stroke, tumors, trauma, and degenerative diseases. Accurate interpretation of axial brain scans requires a solid grasp of the anatomical landmarks discussed above. This detailed knowledge allows clinicians to pinpoint lesions, assess the extent of damage, and plan appropriate interventions.

# Conclusion

Mastering axial brain anatomy is a crucial step towards understanding the intricacies of the human brain. By visualizing the brain in axial slices, we gain a unique perspective on the complex interplay between its different structures. This comprehensive guide has provided a detailed exploration of key anatomical landmarks, their locations, and their functional roles. This knowledge is invaluable for students, healthcare professionals, and anyone with a keen interest in the fascinating world of neuroscience.

# FAQs:

1. What is the difference between axial, sagittal, and coronal views of the brain? Axial views are horizontal slices; sagittal views are vertical slices from front to back; coronal views are vertical slices from side to side. Each provides a unique perspective on the brain's structure.
2. Why is understanding axial brain anatomy important for medical professionals? Accurate interpretation of axial images (like CT and MRI scans) is crucial for diagnosing and managing neurological conditions.
3. Can I learn axial brain anatomy without formal medical training? Yes, with dedication and the right resources (like this guide!), anyone can develop a solid understanding of basic axial brain anatomy.
4. Are there online resources that can help visualize axial brain anatomy? Yes, many interactive brain atlases and online anatomy resources offer 3D visualizations and axial slice views.
5. How can I improve my understanding of axial brain anatomy further? Studying anatomical models, practicing identifying structures on axial images, and consulting medical textbooks and atlases will significantly enhance your understanding.

**axial brain anatomy: *Duvernoy's Atlas of the Human Brain Stem and Cerebellum*** Thomas P. Naidich, Henri M. Duvernoy, Bradley N. Delman, A. Gregory Sorensen, Spyros S. Kollias, E. Mark Haacke, 2009-06-25 This atlas instills a solid knowledge of anatomy by correlating thin-section brain anatomy with corresponding clinical magnetic resonance images in axial, coronal, and sagittal planes. The authors correlate advanced neuromelanin imaging, susceptibility-weighted imaging, and diffusion tensor tractography with clinical 3 and 4 T MRI. Each brain stem region is then analyzed with 9.4 T MRI to show the anatomy of the medulla, pons, midbrain, and portions of the diencephalon with an in-plane resolution comparable to myelin- and Nissl-stained light microscopy. The book's carefully organized diagrams and images teach with a minimum of text.

**axial brain anatomy: *The Human Brain*** Henri M. Duvernoy, 2012-12-06 Serial sections - 2 mm thick - of the cerebral hemispheres and diencephalon in the coronal, sagittal, and horizontal planes. So as to point out the level of the sections more accurately, each is shown from different angles -- emphasising the surrounding hemisphere surfaces. This 3D approach has proven to be extremely useful when apprehending the difficult anatomy of the gyri and sulci of the brain. Certain complex cerebral structures such as the occipital lobe, the deep grey matter and the vascularization are studied here in greater detail. This second edition has been completely revised and updated, 44 serial sections have been added, while old MRI figures have been replaced by newer ones.

**axial brain anatomy: *Atlas of Regional Anatomy of the Brain Using MRI*** Jean C. Tamraz, Youssef Comair, 2006-02-08 A unique review of the essential topographical anatomy of the brain from an MRI perspective, correlating high-quality anatomical plates with high-resolution MRI images. The book includes a historical review of brain mapping and an analysis of the essential reference planes used. It provides a detailed review of the sulcal and the gyral anatomy of the human cortex, guiding readers through an interpretation of the individual brain atlas provided by high-resolution MRI. The relationship between brain structure and function is approached in a topographical fashion with an analysis of the necessary imaging methodology and displayed anatomy. An extensive coronal atlas rounds off the book.

**axial brain anatomy: *Cross-Sectional Atlas of the Human Head*** Jin Seo Park, 2018-01-02

This superb color atlas sets a new standard in neuroanatomy by presenting around 300 detailed thin-sectioned images of the human head, including the brain, with 0.1-mm intervals and a pixel size of 0.1 mm × 0.1 mm. A new reference system employed for this purpose is clearly explained, and structures are fully annotated in the horizontal, coronal, and sagittal planes. Recent advances in 7T MRI and 7T TDI have considerably enhanced imaging of the human brain, thereby impacting on both neuroscience research and clinical practice. Moreover, the information gained from initiatives involving photography of thin slices of human cadavers, such as the Visible Human Projects, Visible Korean and Chinese Visible Human, has enriched knowledge of neuroanatomy and thereby facilitated the interpretation of such ultra-high-field resolution images. The exquisite images contained within this atlas will be invaluable in providing both researchers and clinicians with important new insights.

**axial brain anatomy:** Atlas of Anatomy, Latin Nomenclature Anne M. Gilroy, Brian R. MacPherson, Jamie C. Wikenheiser, 2021-11-19 Quintessential Atlas of Anatomy expands on widely acclaimed prior editions! Atlas of Anatomy, Latin Nomenclature, Fourth Edition builds on its longstanding reputation of being the highest-quality anatomy atlas published to date using Latin nomenclature. With more than 2,000 exquisitely detailed illustrations, including over 120 new to this edition, the Atlas helps students and seasoned clinicians master the details of human anatomy. Key Features: NEW! Expanded Radiology sections include over 40 new radiographs, CTs, and MRIs NEW! A more dissectional approach to the head and neck region places neck anatomy before that of the head – the way most students dissect NEW! Additional images and tables detail the challenging anatomy of the peritoneal cavity, inguinal region, and infratemporal and pterygopalatine fossae NEW! Almost 30 new clinical boxes focus on function, pathology, diagnostic techniques, anatomic variation, and more NEW! More comprehensive coverage clarifies the complexities of the ANS, including revised wiring schematics Also included in this new edition: Muscle Fact spreads provide origin, insertion, innervation, and action An innovative, user-friendly format: every topic covered in two side-by-side pages Online images with labels-on and labels-off capability are ideal for review and self-testing What users say about the Atlas of Anatomy: I can't say enough how much I like the organization of this text. I think Thieme has 'hit the nail on the head' with structuring everything by region (Lower Limb) and sub-region (Ankle & Foot). It's very easy to find what you're looking for... The figures in the Atlas of Anatomy are exemplary and surpass other competing texts. The images are clear, precise, and aesthetically colored. The unique views presented in this work are also very helpful for studying a three-dimensional subject such as human anatomy.

**axial brain anatomy:** *See Right Through Me* Savvas Andronikou, 2012-12-04 This atlas demonstrates all components of the body through imaging, in much the same way that a geographical atlas demonstrates components of the world. Each body system and organ is imaged in every plane using all relevant modalities, allowing the reader to gain knowledge of density and signal intensity. Areas and methods not usually featured in imaging atlases are addressed, including the cranial nerve pathways, white matter tractography, and pediatric imaging. As the emphasis is very much on high-quality images with detailed labeling, there is no significant written component; however, 'pearl boxes' are scattered throughout the book to provide the reader with greater insight. This atlas will be an invaluable aid to students and clinicians with a radiological image in hand, as it will enable them to look up an exact replica and identify the anatomical components. The message to the reader is: Choose an organ, read the 'map,' and enjoy the journey!

**axial brain anatomy:** *7.0 Tesla MRI Brain Atlas* Zang-Hee Cho, 2010-03-20 Recent advances in MRI, especially those in the area of ultra high field (UHF) MRI, have attracted significant attention in the field of brain imaging for neuroscience research, as well as for clinical applications. In 7.0 Tesla MRI Brain Atlas: In Vivo Atlas with Cryomacrotome Correlation, Zang-Hee Cho and his colleagues at the Neuroscience Research Institute, Gachon University of Medicine and Science set new standards in neuro-anatomy. This unprecedented atlas presents the future of MR imaging of the brain. Taken at 7.0 Tesla, the images are of a live subject with correlating cryomacrotome photographs. Exquisitely produced in an oversized format to allow careful examination of the brain

in real scale, each image is precisely annotated and detailed. The images in the Atlas reveal a wealth of details of the main stem and midbrain structures that were once thought impossible to visualize in-vivo. Ground breaking and thought provoking, 7.0 Tesla MRI Brain Atlas is sure to provide answers and inspiration for further studies, and is a valuable resource for medical libraries, neuroradiologists and neuroscientists.

**axial brain anatomy: Atlas of Human Brain Connections** Marco Catani, Michel Thiebaut de Schotten, 2012-06-14 One of the major challenges of modern neuroscience is to define the complex pattern of neural connections that underlie cognition and behaviour. This atlas capitalises on novel diffusion MRI tractography methods to provide a comprehensive overview of connections derived from virtual in vivo tractography dissections of the human brain.

**axial brain anatomy: Diseases of the Brain, Head and Neck, Spine 2020-2023** Juerg Hodler, Rahel A. Kubik-Huch, Gustav K. von Schulthess, 2020-02-14 This open access book offers an essential overview of brain, head and neck, and spine imaging. Over the last few years, there have been considerable advances in this area, driven by both clinical and technological developments. Written by leading international experts and teachers, the chapters are disease-oriented and cover all relevant imaging modalities, with a focus on magnetic resonance imaging and computed tomography. The book also includes a synopsis of pediatric imaging. IDKD books are rewritten (not merely updated) every four years, which means they offer a comprehensive review of the state-of-the-art in imaging. The book is clearly structured and features learning objectives, abstracts, subheadings, tables and take-home points, supported by design elements to help readers navigate the text. It will particularly appeal to general radiologists, radiology residents, and interventional radiologists who want to update their diagnostic expertise, as well as clinicians from other specialties who are interested in imaging for their patient care.

**axial brain anatomy: The Human Brain Stem and Cerebellum** Henri M. Duvernoy, 2012-12-06 This study of the brain stem and the cerebellum is the sequel to a previous study of the brain (cerebral hemispheres and diencephalon) [82]. The brain stem and cerebellum are dealt with here for the same purpose as was the brain in the previous work, i.e., to reach, step by step, knowledge that is comprehensive enough for an understanding of an atlas of sections and its clinical use. Following a brief survey of the methods used, the first chapter describes the brain stem and cerebellum surfaces as well as their location in the posterior cranial fossa. The second and the third chapter, respectively, describe the brain stem and cerebellum structures followed by brief surveys of their functions, enabling the reader to obtain an introductory view of the role of both the nuclei and fasciculi. The fourth chapter studies the brain stem vascular network in detail. Thus, this chapter sums up the results of research on brainstem superficial blood vessels and their intra nervous territories that were already presented in two previous works [79, 80]. By contrast, presentation of the cerebellar vascularization follows the previous literature.

**axial brain anatomy: Anatomy and Physiology** J. Gordon Betts, Peter DeSaix, Jody E. Johnson, Oksana Korol, Dean H. Kruse, Brandon Poe, James A. Wise, Mark Womble, Kelly A. Young, 2013-04-25

**axial brain anatomy: Functional Brain Imaging** William W. Orrison, Jeffrey Lewine, John Sanders, Michael F. Hartshorne, 2017-02-24 Functional Brain Imaging

**axial brain anatomy: Atlas of Brain Function** William W. Orrison, 2008 A new edition of the lavishly illustrated guide to brain structure and function This atlas is an outstanding single-volume resource of information on the structure and function of specific areas of the brain. Updated to reflect the latest technology using 3 Tesla MR images, this edition has been enhanced with new functional MRI studies as well as a new section on diffusion tensor imaging with three-dimensional reconstructions of fiber tracts using color coding to demonstrate neural pathways. Highlights: Glossary of neuroanatomic structures and definitions provides the reader with a foundation in structures, function, and functional relationships High-quality images are divided into five sections, including Sagittal MRI views, Axial MRI views, Coronal MRI views, Fiber-Tracking Diffusion Tensor Imaging, and Three-Dimensional MRI views Icons rapidly orient the reader with the location of each

view or the diffusion pathway This book eliminates the need to sift through multiple books for the current information on the structure and function of the brain. It is invaluable for clinicians in radiology, neuroradiology, neurology, neurosurgery, psychiatry, psychology, neuropsychology, and neuroanatomy. The atlas is also ideal for medical students, nursing students, and individuals seeking to gain a firm understanding of human brain anatomy and function.

**axial brain anatomy:** *Sectional Anatomy of the Human Brain*, 2000

**axial brain anatomy: Atlas of Neuroradiologic Embryology, Anatomy, and Variants J.** Randy Jenkins, 2000 This comprehensive atlas depicts the entire range of normal variants seen on neuroradiologic images, helping radiologists decode appearances that can be misdiagnosed as pathology. The book features nearly 900 radiographs that show normal variants seen on plain film, MR, CT, and angiographic images, plus accompanying line drawings that demonstrate normal angiogram patterns and other pertinent anatomy. Dr. Jenkins, a well-known neuroradiologist, takes a multimodality approach to the cranium, sella, orbit, face, sinuses, neck, and spine. In an easy-to-follow format, he provides the information radiologists need to identify unusual features...assess their significance...avoid unnecessary, expensive studies...and minimize exposure and risk.

**axial brain anatomy: Applied Cranial-Cerebral Anatomy** Guilherme C. Ribas, 2018-03  
Historical remarks -- The cerebral architecture -- Cranial-cerebral relationships applied to microneurosurgery

**axial brain anatomy: Anatomy & Physiology** Lindsay Biga, Devon Quick, Sierra Dawson, Amy Harwell, Robin Hopkins, Joel Kaufmann, Mike LeMaster, Philip Matern, Katie Morrison-Graham, Jon Runyeon, 2019-09-26 A version of the OpenStax text

**axial brain anatomy: Imaging of the Brain** Thomas P. Naidich, MD, Mauricio Castillo, MD, Soonmee Cha, MD, James G. Smirniotopoulos, MD, 2012-10-31 Imaging of the Brain provides the advanced expertise you need to overcome the toughest diagnostic challenges in neuroradiology. Combining the rich visual guidance of an atlas with the comprehensive, in-depth coverage of a definitive reference, this significant new work in the Expert Radiology series covers every aspect of brain imaging, equipping you to make optimal use of the latest diagnostic modalities. Compare your clinical findings to more than 2,800 digital-quality images of both radiographic images and cutting edge modalities such as MR, multislice CT, ultrasonography, and nuclear medicine, including PET and PET/CT. Visualize relevant anatomy more easily thanks to full-color anatomic views throughout. Choose the most effective diagnostic options, with an emphasis on cost-effective imaging. Apply the expertise of a diverse group of world authorities from around the globe on imaging of the brain. Use this reference alongside Dr. Naidich's Imaging of the Spine for complementary coverage of all aspects of neuroimaging. Access the complete contents of Imaging of the Brain online and download all the images at [www.expertconsult.com](http://www.expertconsult.com).

**axial brain anatomy: Introduction to Neuroimaging Analysis** Mark Jenkinson, Michael Chappell, 2018 This accessible primer gives an introduction to the wide array of MRI-based neuroimaging methods that are used in research. It provides an overview of the fundamentals of what different MRI modalities measure, what artifacts commonly occur, the essentials of the analysis, and common 'pipelines'.

**axial brain anatomy: Clinical Neuroradiology** Frederik Barkhof, Rolf Jäger, Majda Thurnher, Alex Rovira, 2019-04-16 This superbly illustrated textbook, endorsed by the European Society of Neuroradiology, explains in detail the clinical importance of neuroradiology in complementing history taking and physical examination during the workup of patients suspected of having neurological, neurosurgical, or psychiatric disorders. The role of imaging of the brain and spinal cord is described across the full range of relevant conditions, including, for example, cerebrovascular diseases, trauma, CSF disorders, developmental malformations, autoimmune diseases, epilepsy, tumors and tumor-like conditions, neurodegenerative diseases, metabolic conditions, and bipolar and depressive disorders. The structured approach to imaging and image analysis will ensure that the book is an invaluable resource for neuroradiologists in training and

clinicians alike. Starting from the clinical indication, suggestions for imaging protocols are provided and checklists of common findings and aspects key to interpretation are presented. The book is published within the SpringerReference program, which combines thorough coverage with access to living editions constantly updated via a dynamic peer-review process.

**axial brain anatomy:** Atlas of Imaging Anatomy Lucio Olivetti, 2014-12-19 This book is designed to meet the needs of radiologists and radiographers by clearly depicting the anatomy that is generally visible on imaging studies. It presents the normal appearances on the most frequently used imaging techniques, including conventional radiology, ultrasound, computed tomography, and magnetic resonance imaging. Similarly, all relevant body regions are covered: brain, spine, head and neck, chest, mediastinum and heart, abdomen, gastrointestinal tract, liver, biliary tract, pancreas, urinary tract, and musculoskeletal system. The text accompanying the images describes the normal anatomy in a straightforward way and provides the medical information required in order to understand why we see what we see on diagnostic images. Helpful correlative anatomic illustrations in color have been created by a team of medical illustrators to further facilitate understanding.

**axial brain anatomy:** The Brain and Behavior David L. Clark, Nashaat N. Boutros, Mario F. Mendez, 2005-09-08 New edition building on the success of previous one. Retains core aim of providing an accessible introduction to behavioral neuroanatomy.

**axial brain anatomy:** Make Life Visible Yoshiaki Toyama, Atsushi Miyawaki, Masaya Nakamura, Masahiro Jinzaki, 2019-10-02 This open access book describes marked advances in imaging technology that have enabled the visualization of phenomena in ways formerly believed to be completely impossible. These technologies have made major contributions to the elucidation of the pathology of diseases as well as to their diagnosis and therapy. The volume presents various studies from molecular imaging to clinical imaging. It also focuses on innovative, creative, advanced research that gives full play to imaging technology in the broad sense, while exploring cross-disciplinary areas in which individual research fields interact and pursuing the development of new techniques where they fuse together. The book is separated into three parts, the first of which addresses the topic of visualizing and controlling molecules for life. The second part is devoted to imaging of disease mechanisms, while the final part comprises studies on the application of imaging technologies to diagnosis and therapy. The book contains the proceedings of the 12th Uehara International Symposium 2017, "Make Life Visible" sponsored by the Uehara Memorial Foundation and held from June 12 to 14, 2017. It is written by leading scientists in the field and is an open access publication under a CC BY 4.0 license.

**axial brain anatomy:** The Cerebellum and Cognition , 1997-10-02 The Cerebellum and Cognition pulls together a preeminent group of authors. The cerebellum has been previously considered as a highly complex structure involved only with motor control. The cerebellum is essential to nonmotor functions, and recent research has revealed new medically important roles of the cerebellum and cognitive processes. - Selected for inclusion in Doody's Core Titles 2013, an essential collection development tool for health sciences libraries - Comprehensive coverage of cerebellum in motor control and cognition - New developments regarding the cerebellum and motor systems - Therapeutic implications of cerebellar contributions to cognition - Preeminent group of contributors

**axial brain anatomy:** Atlas of Morphology and Functional Anatomy of the Brain T. Scarabino, U. Salvolini, 2010-02-12 The recent advances in neuroimaging techniques, particularly magnetic resonance (MR), have greatly improved our knowledge of brain anatomy and related brain function. Morphological and functional investigations of the brain using high-definition MR have made detailed study of the brain possible and provided new data on anatomo-functional correlations. These studies have fuelled the interest in central nervous system imaging by clinicians (neuroradiologists, neurosurgeons, neurologists, neurophysiologists, and psychiatrists) as well as biophysicists and bioengineers, who are at work on new and ever more sophisticated acquisition and processing techniques to continue to improve the potential of brain imaging methods. The possibility of obtaining high-definition MR images using a 3.0-T magnet prompted us, despite the broad existing

literature, to conceive an atlas illustrating in a simple and effective way the anatomy of the brain and correlated functions. Following an introductory chapter by Prof. Pierre Rabischong, the atlas is divided into a morphological and a functional imaging section. The morphological atlas includes 3D surface images, axial, coronal, and sagittal scans acquired with high-definition T2 fast spin echo (FSE) sequences, and standard and inverted-contrast images. The MR scans are shown side by side with the corresponding anatomical brain sections, provided by Prof. Henri Duvernoy, for more effective comparison. The anatomical nomenclature adopted for both the MR and the anatomical images is listed in an jacket flap for easier consultation.

**axial brain anatomy: Neuroanatomy of Language Regions of the Human Brain** Michael Petrides, 2013-12-03 Many studies of the neural bases of language processes are now conducted with functional and structural neuroimaging. Research is often compromised because of difficulties in identifying the core structures in the face of the complex morphology of these regions of the brain. Although there are many books on the cognitive aspects of language and also on neurolinguistics and aphasiology, *Neuroanatomy of Language Regions of the Human Brain* is the first anatomical atlas that focuses on the core regions of the cerebral cortex involved in language processing. This atlas is a richly illustrated guide for scientists interested in the gross morphology of the sulci and gyri of the core language regions, in the cytoarchitecture of the relevant cortical areas, and in the connectivity of these areas. Data from diffusion MRI and resting-state connectivity are integrated with critical experimental anatomical data about homologous areas in the macaque monkey to provide the latest information on the connectivity of the language-relevant cortical areas of the brain. Although the anatomical connectivity data from studies on the macaque monkey provide the most detailed information, they are often neglected because of difficulties in interpreting the terminology used and in making the monkey-to-human comparison. This atlas helps investigators interpret this important source of information. *Neuroanatomy of Language Regions of the Human Brain* will assist investigators of the neural bases of language in increasing the anatomical sophistication of their research and in evaluating studies of language and the brain. - Abundantly illustrated with photographs, 3-D MRI reconstructions, and sections to represent the morphology of the sulci and gyri in the frontal, temporal, and parietal regions involved in language processing - Photomicrographs showing the cytoarchitecture of cortical areas involved in language processing - Series of coronal, sagittal, and horizontal sections identifying the sulci and gyri to assist language investigators using structural and functional neuroimaging techniques - All images accompanied by brief commentaries to help users navigate the complexities of the anatomy - Integration of data from diffusion MRI and resting-state connectivity with critical experimental anatomical data on the connectivity of homologous areas in the macaque monkey

**axial brain anatomy: Applied Cerebral Angiography** Gianni Boris Bradac, 2017-09-07 This book offers detailed guidance on the diagnostic use of cerebral angiography based on precise description of the angiographic appearances of normal anatomy and pathological conditions. In this third edition, every chapter has been thoroughly revised and enlarged to reflect new knowledge and experiences, and more attention is paid to the correlations between anatomopathological findings and clinical manifestations. Beyond explaining the diagnostic value of cerebral angiography, a key aim is to equip readers with the precise knowledge of the anatomy of cerebral vessels required for optimal application of endovascular therapy of pathologies involving the arteries and veins of the brain. As in preceding editions, the book is divided into two parts. The first part describes the normal anatomy, with attention to morphological aspects, embryological development, function, and vascular territories. The intraorbital and extracranial vascularization is also fully considered. The knowledge provided will serve as a sound basis for the correct interpretation of pathological processes and their clinical significance, as covered in depth in the second part of the book.

**axial brain anatomy: Micro-, Meso- and Macro-Connectomics of the Brain** Henry Kennedy, David C. Van Essen, Yves Christen, 2016-03-10 This book has brought together leading investigators who work in the new arena of brain connectomics. This includes 'macro-connectome' efforts to comprehensively chart long-distance pathways and functional networks; 'micro-connectome' efforts

to identify every neuron, axon, dendrite, synapse, and glial process within restricted brain regions; and 'meso-connectome' efforts to systematically map both local and long-distance connections using anatomical tracers. This book highlights cutting-edge methods that can accelerate progress in elucidating static 'hard-wired' circuits of the brain as well as dynamic interactions that are vital for brain function. The power of connectomic approaches in characterizing abnormal circuits in the many brain disorders that afflict humankind is considered. Experts in computational neuroscience and network theory provide perspectives needed for synthesizing across different scales in space and time. Altogether, this book provides an integrated view of the challenges and opportunities in deciphering brain circuits in health and disease.

**axial brain anatomy: Brain Anatomy and Neurosurgical Approaches** Eberval Gadelha Figueiredo, Nícollas Nunes Rabelo, Leonardo Christiaan Welling, 2023-04-28 This strategic book joins the classical brain anatomy to the challenges of neurosurgery approaches. Its thirty illustrated chapters connect basic concepts to the specialists experience in the operating room. They also provide didactic tips and tricks for accessing the brain into to the surface, cisterns, central core, ventricles and skull base. The Brain Anatomy and Neurosurgical Approaches is focused on neurosurgeons in training and those who need updated information and technical tips on how to deal with neurosurgical patients, as well as with anatomical challenges in real surgeries. Neurosurgeons, residents and students will have a helpful source of study and research.

**axial brain anatomy: Neuroanatomy** Duane E. Haines, 2004 The Sixth Edition of Dr. Haines's best-selling neuroanatomy atlas features a stronger clinical emphasis, with significantly expanded clinical information and correlations. More than 110 new images--including MRI, CT, MR angiography, color line drawings, and brain specimens--highlight anatomical-clinical correlations. Internal spinal cord and brainstem morphology are presented in a new format that shows images in both anatomical and clinical orientations, correlating this anatomy exactly with how the brain and its functional systems are viewed in the clinical setting. A new chapter contains over 235 USMLE-style questions, with explained answers. This edition is packaged with Interactive Neuroanatomy, Version 2, an interactive CD-ROM containing all the book's images.

**axial brain anatomy: Clinical Emergency Radiology** J. Christian Fox, 2017-03-16 This book is a highly visual guide to the radiographic and advanced imaging modalities - such as computed tomography and ultrasonography - that are frequently used by physicians during the treatment of emergency patients. Covering practices ranging from ultrasound at the point of care to the interpretation of CT scan results, this book contains over 2,200 images, each with detailed captions and line-art that highlight key findings. Within each section, particular attention is devoted to practical tricks of the trade and tips for avoiding common pitfalls. Overall, this book is a useful source for experienced clinicians, residents, mid-level providers, or medical students who want to maximize the diagnostic accuracy of each modality without losing valuable time.

**axial brain anatomy: Imaging Anatomy of the Human Brain** Neil M. Borden, MD, Cristian Stefan, MD, Scott E. Forseen, MD, 2015-08-25 An Atlas for the 21st Century The most precise, cutting-edge images of normal cerebral anatomy available today are the centerpiece of this spectacular atlas for clinicians, trainees, and students in the neurologically-based medical and non-medical specialties. Truly an atlas for the 21st century, this comprehensive visual reference presents a detailed overview of cerebral anatomy acquired through the use of multiple imaging modalities including advanced techniques that allow visualization of structures not possible with conventional MRI or CT. Beautiful color illustrations using 3-D modeling techniques based upon 3D MR volume data sets further enhances understanding of cerebral anatomy and spatial relationships. The anatomy in these color illustrations mirror the black and white anatomic MR images presented in this atlas. Written by two neuroradiologists and an anatomist who are also prominent educators, along with more than a dozen contributors, the atlas begins with a brief introduction to the development, organization, and function of the human brain. What follows is more than 1,000 meticulously presented and labelled images acquired with the full complement of standard and advanced modalities currently used to visualize the human brain and adjacent structures including

MRI, CT, diffusion tensor imaging (DTI) with tractography, functional MRI, CTA, CTV, MRA, MRV, conventional 2-D catheter angiography, 3-D rotational catheter angiography, MR spectroscopy, and ultrasound of the neonatal brain. The vast array of data that these modes of imaging provide offers a wider window into the brain and allows the reader a unique way to integrate the complex anatomy presented. Ultimately the improved understanding you can acquire using this atlas can enhance clinical understanding and have a positive impact on patient care. Additionally, various anatomic structures can be viewed from modality to modality and from multiple planes. This state-of-the-art atlas provides a single source reference, which allows the interested reader ease of use, cross-referencing, and the ability to visualize high-resolution images with detailed labeling. It will serve as an authoritative learning tool in the classroom, and as an invaluable practical resource at the workstation or in the office or clinic. Key Features: Provides detailed views of anatomic structures within and around the human brain utilizing over 1,000 high quality images across a broad range of imaging modalities Contains extensively labeled images of all regions of the brain and adjacent areas that can be compared and contrasted across modalities Includes specially created color illustrations using computer 3-D modeling techniques to aid in identifying structures and understanding relationships Goes beyond a typical brain atlas with detailed imaging of skull base, calvaria, facial skeleton, temporal bones, paranasal sinuses, and orbits Serves as an authoritative learning tool for students and trainees and practical reference for clinicians in multiple specialties

**axial brain anatomy: Human Brain Anatomy in Computerized Images** Hanna Damasio M.D., 2005-03-24 By using non-invasive tomographic scans, modern neuroimaging technologies are revealing the structure of the human brain in unprecedented detail. This spectacular progress, however, poses a critical problem for neuroscientists and for practitioners of brain-related professions: how to find their way in the current tomographic images so as to identify a particular brain site, be it normal or damaged by disease? Prepared by a leading expert in advanced brain-imaging techniques, this unique atlas is a guide to the localization of brain structures that illustrates the wide range of neuroanatomical variation. It is based on the analysis of 29 normal human brains obtained from three-dimensional reconstructions of magnetic resonance scans of living persons. The Second Edition of this atlas offers entirely new images, all from new brain specimens.

**axial brain anatomy: In Vivo Atlas of Deep Brain Structures** S. Lucerna, F.M. Salpietro, C. Alafaci, F. Tomasello, 2002-01-29 This 'in vivo' atlas contains more than 50 magnetic resonance (MR) images of the brain. Each structure is represented in the axial, coronal and sagittal plane, magnified in colour schemes and reconstructed in 3D images with a useful millimetric scale. The atlas offers the reader a practical and simple tool for surgical planning and for diagnostic and anatomical studies. The high level of anatomical definition of the in vivo MR images means that there is no loss in precision as a result of post-mortem changes. No doubt, this book is an excellent teaching instrument for all students of the neurosciences, regardless of the individual level of training and expertise.

**axial brain anatomy: Functional Anatomy of the Brain: A View from the Surgeon's Eye** Abhidha Shah, Atul Goel, Yoko Kato, 2023-11-28 This book essentially provides a refreshing description of the cortical and subcortical anatomy of the brain and how it relates to function. It includes subtleties of anatomy, advances in imaging, operative nuances, techniques, and a brief discussion about artificial intelligence. It discusses surgical strategies on intrinsic brain tumors in general and gliomas in particular with several images. The issues that need to be considered in decision-making are explained in this book. The best surgical options are described step-by-step. The relevant anatomy and function of the region are discussed and show the consequences of the damage. This book covers the intra-operative nuances to prevent neurological morbidity. Modern imaging features that help during surgery and decision-making are elaborated. The book is heavily illustrated with anatomical images, intraoperative images, radiologic images, and drawings supported by videos of the surgical approaches and techniques. The chapter structure involves

reoccurring headings, didactic elements such as chapter summaries, boxes (note, caution), bullet points, tables, flowcharts, key points. This book is handy for neurosurgeons, especially neuro-oncologists, which helps keep them abreast with the advances in the field.

**axial brain anatomy: Anatomy in Diagnostic Imaging** Peter Fleckenstein, Jørgen Tranum-Jensen, 2014-07-25 Now in its third edition, *Anatomy in Diagnostic Imaging* is an unrivalled atlas of anatomy applied to diagnostic imaging. The book covers the entire human body and employs all the imaging modalities used in clinical practice; x-ray, CT, MR, PET, ultrasound and scintigraphy. An introductory chapter explains succinctly the essentials of the imaging and examination techniques drawing on the latest technical developments. In view of the great strides that have been made in this area recently, all chapters have been thoroughly revised in this third edition. The book's original and didactically convincing presentation has been enhanced with over 250 new images. There are now more than 900 images, all carefully selected in order to be user-friendly and easy-to-read, due to their high quality and the comprehensive anatomical interpretation directly placed alongside every one. Both for medical students and practising doctors, *Anatomy in Diagnostic Imaging* will serve as the go-to all-round reference collection linking anatomy and modern diagnostic imaging. Winner of the Radiology category at the BMA Book Awards 2015

**axial brain anatomy: Imaging Acute Neurologic Disease** Massimo Filippi, Jack H. Simon, 2014-09-11 A comprehensive survey of best practice in using diagnostic imaging in acute neurologic conditions. The symptom-based approach guides the choice of the available imaging tools for efficient, accurate, and cost-effective diagnosis. Effective examination algorithms integrate neurological and imaging concepts with the practical demands and constraints of emergency care.

**axial brain anatomy: Radiographic Atlas of Skull and Brain Anatomy** Massimo Gallucci, Silvia Capoccia, Alessia Catalucci, 2007-12-05 The English Edition contains a few differences from the first Italian Edition, which require an explanation. Firstly, some images, especially some 3D reconstructions, have been modified in order to make them clearer. Secondly, in agreement with the Publisher, we have disowned one of our statements in the preface to the Italian Edition. Namely, we have now added a brief introductory text for each section, by way of explanation to the anatomical and physiological notes. This should make it easier for the reader to understand and refer to this Atlas. These differences derive from our experience with the previous edition and are meant to be an improvement thereof. Hopefully, there will be more editions to follow, so that we may further improve our work and keep ourselves busy on some evenings. Finally, the improvements in this edition are a reminder to the reader that one should never purchase the first edition of a work. *UAquila*, January 2006 The Authors Preface to the Italian Edition I have been meaning to publish an atlas of neuroradiologic cranio-encephalic anatomy for at least the last decade. Normal anatomy has always been of great and charming interest to me. Over the years, while preparing lectures for my students, I have always enjoyed lingering on anatomical details that today are rendered with astonishing realism by routine diagnostic imaging.

**axial brain anatomy: Human Sectional Anatomy** Harold Ellis, Bari M Logan, Adrian K. Dixon, 2009-09-25 First published in 1991, *Human Sectional Anatomy* set new standards for the quality of cadaver sections and accompanying radiological images. Now in its third edition, this unsurpassed quality remains and is further enhanced by some useful new material. As with the previous editions, the superb full-colour cadaver sections are compared with CT and MRI images, with accompanying, labelled line diagrams. Many of the radiological images have been replaced with new examples, taken on the most up-to-date equipment to ensure excellent visualisation of the anatomy. Completely new page spreads have been added to improve the book's coverage, including images taken using multidetector CT technology, and some beautiful 3D volume rendered CT images. The photographic material is enhanced by useful notes, extended for the third edition, with details of important anatomical and radiological features.

**axial brain anatomy: Gupta and Gelb's Essentials of Neuroanesthesia and Neurointensive Care** Arun Gupta, Adrian Gelb, Ram Adapa, Derek Duane, 2018-06-21 This second edition presents core clinical neuroanesthesia and neurointensive care knowledge in a practical, user-friendly format.

### Cross-sectional anatomy of the brain: normal anatomy | e-Anatomy

We created a brain atlas that is an interactive tool for studying the conventional anatomy of the normal brain based on a magnetic resonance imaging exam of the axial brain. Anatomical ...

### *MRI anatomy | Free MRI Axial Brain Anatomy - mrimaster*

This MRI brain cross sectional anatomy tool is absolutely free to use. This section of the website will explain large and minute details of axial brain cross sectional anatomy.

### *Brain lobes - annotated MRI | Radiology Case | Radiopaedia.org*

Brain MRI (FLAIR) with annotations of major structures.

### *Brain Anatomy - The Radiology Assistant*

Nov 24, 2008 · Anterior cerebral artery from carotid bifurcation to anterior communicating artery gives rise to the medial lenticulostriate arteries. Part of anterior cerebral artery distal to the ...

### **Brain | Radiology Key**

Apr 4, 2019 · The interpeduncular cistern is a good anatomic feature to scrutinize; this location often first reveals subarachnoid hemorrhage when a brain aneurysm ruptures. This usually ...

### **The Whole Brain Atlas - Harvard Medical School**

Can you name these brain structures?

### **MRI Cross-Sectional Anatomy of the Brain - virtual-body.org**

This is one of 36 interactive scenes of the VOXEL-MAN 3D Navigator: Brain and Skull anatomical atlas. In this scene, you can browse through axial cross-sectional images of the head from ...

### *Cross-sectional anatomy of the brain: normal anatomy | e-Anatomy*

We created a brain atlas that is an interactive tool for studying the conventional anatomy of the normal brain based on a magnetic resonance imaging exam of the axial brain. Anatomical ...

### MRI anatomy | Free MRI Axial Brain Anatomy - mrimaster

This MRI brain cross sectional anatomy tool is absolutely free to use. This section of the website will explain large and minute details of axial brain cross sectional anatomy.

### **Brain lobes - annotated MRI | Radiology Case | Radiopaedia.org**

Brain MRI (FLAIR) with annotations of major structures.

### **Brain Anatomy - The Radiology Assistant**

Nov 24, 2008 · Anterior cerebral artery from carotid bifurcation to anterior communicating artery gives rise to the medial lenticulostriate arteries. Part of anterior cerebral artery distal to the ...

### *Brain | Radiology Key*

Apr 4, 2019 · The interpeduncular cistern is a good anatomic feature to scrutinize; this location often first reveals subarachnoid hemorrhage when a brain aneurysm ruptures. This usually ...

### The Whole Brain Atlas - Harvard Medical School

Can you name these brain structures?

### **MRI Cross-Sectional Anatomy of the Brain - virtual-body.org**

This is one of 36 interactive scenes of the VOXEL-MAN 3D Navigator: Brain and Skull anatomical atlas. In this scene, you can browse through axial cross-sectional images of the head from ...

[Back to Home](#)